

Chapter 15

All chapters, full text, free download, available at <http://www.divingmedicine.info>

DECOMPRESSION SICKNESS CLINICAL FEATURES

ACUTE DECOMPRESSION ILLNESS (ADI)

Although the term ADI can cover all types of DCS and barotraumas, it is commonly limited DCS and arterial gas embolism (AGE) from pulmonary barotrauma. Neurological DCS and AGE may be difficult to distinguish as they share similar symptoms - and the initial first aid treatment is similar. Rarely the diseases may even co-exist. Combining the two diseases under a common presentation is of value to those who find them difficult to distinguish from history, symptomatology and clinical signs.

Eventually, both in definitive treatment and in planning future advice to the diver, it is necessary to be more specific.

CLASSIFICATION OF SYMPTOMS

In the past it was traditional to describe decompression sickness (DCS) as Type 1 (minor – musculo-skeletal or joint) or Type 2 (serious - cardio-pulmonary and neurological) DCS. Now the convention is to classify the clinical features according to the organ or system involved (e.g. neurological, musculo-skeletal etc.). It is prudent to include with this diagnosis an indication of the evolution of the symptoms (as described later), as both influence the treatment required.

ONSET OF SYMPTOMS

The clinical features of DCS are seen during or after ascent. In the majority of cases, symptoms will be evident within six hours, and 50% within the first hour of the dive. Less commonly, a delay in onset of 24 hours or greater has been described. Divers often deny the reality of their symptoms, or will rationalise them. In one large series, only half the divers requested assistance within 12 hours of the first symptom developing.

The time of onset of symptoms depends to some degree on the type of dive. Deep dives (greater than 30 metres), especially those that require decompression or are close to the no-decompression limits or in which decompression has been omitted, are likely to present early. In extreme cases, symptoms may present during ascent or at the decompression stops. In general, the earlier the symptoms, the more potentially serious the DCS.

Symptoms may be initiated or aggravated by exposure to altitude (driving over mountains, air travel), exercise or breathing certain gases. Divers should be advised of the potentially serious complications of flying after diving.

JOINT PAIN (MUSCULO-SKELETAL DCS, BENDS)

Pain in or near one of the muscles or tendons around the joints is the **most common presenting feature of DCS from shallow diving**. The shoulder is most often affected while the elbows, wrists, hand, hips, knees, ankles are less frequent. It is not unusual for two joints to be affected, commonly adjacent ones e.g. the shoulder and elbow on the same side. It is less common for multiple joints to be affected in a symmetrical pattern.

Symptoms may begin with discomfort or an abnormal feeling in or near the joint. Over the next hour or two, pain and other symptoms may develop. The pain is generally of a constant aching quality (like a toothache), but occasionally may be throbbing. The diver may hold the joint in a bent position to reduce the pain. The stooping posture, that was adopted by Caisson (tunnel) workers affected by DCS near the hip, led to the term "bends".

The joint is usually not tender to touch but movement may aggravate the pain. Pressure, as from a blood pressure cuff (sphygmomanometer), may relieve the pain.

If not treated, pain usually continues for several uncomfortable days before slowly subsiding. In mild cases, minor and fleeting discomfort lasting only a few hours ("**niggles**") may be the only manifestation.

Symptoms are often found around a joint which has been subjected to unusual exertion or strain during or after the dive or which has been involved in a recent or chronic injury.

There may occasionally be difficulty distinguishing between DCS and other causes of a painful joint such as strain, injury or arthritis. In the latter conditions, the joint is usually tender to touch and may be red and swollen. Generalised arthritis is often bilateral and

symmetrical and involves smaller joints, and local pressure application produces no relief. These signs are uncommon in DCS.

In general, any pain in or near a joint after compressed air dives in excess of 10 metres (or shallower with repetitive or prolonged dives) must be assumed to be DCS until proven otherwise.

NEUROLOGICAL DCS

DCS can affect the **brain, spinal cord and/or peripheral nerves**. The clinical features are due to disturbance of activity in the nervous system, interfering with one or more of its five principal functions:

- **sensation**
- **movement** (including balance and co-ordination)
- **consciousness** and intellectual functions
- **autonomic** functions
- **reflexes** (e.g. knee jerk, cough reflex).

Of these, the first four are easier for the layman to assess.

The Senses.

These include sight, hearing, smell, taste, pain and touch. Numbness and tingling (paraesthesiae) are frequent symptoms. Other abnormal signs include loss of sensation.

Movement.

This includes the ability to move any muscle, the strength of the movement and the ability to co-ordinate it.

Higher function of the brain.

The important intellectual functions are consciousness, orientation (awareness of time, person and place), thinking, speech and memory. Epileptic fits (convulsions) and confusion are possible. See the AMTS box at the end of this chapter for a rapid, simple method of assessing higher function brain involvement.

Autonomic functions.

Interference with the control of breathing and heart function may cause shock and collapse. Bladder and bowel malfunction usually causes progressive abdominal discomfort and tenderness until the bladder or bowels are opened.

In **CEREBRAL (Brain) DCS**, the bubbles of DCS may be located in or near the blood vessels supplying the brain, causing obstruction of blood flow and direct pressure on the neurological tissues. The brain swells like any other tissue when injured, but because it is

confined within the solid bone of the skull, the pressure in the skull rises, further impairing blood supply to other parts of the brain. Swelling of the brain (cerebral oedema), as well as expansion of the nitrogen bubbles themselves, often leads to a steady worsening of this condition.

The onset of cerebral DCS is often heralded by **headache** — probably due to brain swelling. **Numbness** or **tingling (paraesthesiae)**, **weakness** or **paralysis** affecting a limb or one side of the body, difficulty with **speech**, **visual** disturbances, **confusion**, loss of **consciousness** or **convulsions** are all possible presenting symptoms of this serious disorder.

The part of the brain responsible for co-ordination (the cerebellum) may also be affected causing incoordination known as "**staggers**". The position sense and the balance organs can also be affected.

SPINAL DCS has a common association with DCS bubbles in the blood and lungs, commonly known as "**chokes**". It also may be preceded by "**girdle pains**" — or pain around the chest or abdomen. Disturbances in movement such as **weakness** or **paralysis** or disturbances in sensation such as **numbness** or **tingling** are also common. Interference with nerve supply to the bladder and intestines, may lead to **difficulty in passing urine, or opening the bowel**. **Paraplegia** or **quadriplegia** may develop.

INNER EAR DCS

The cochlea (hearing) or vestibular (balance) organs may be involved. This type of DCS is more commonly associated with **prolonged, deep, repetitive, diving, breathing a helium-oxygen mixture**. **Hearing loss**, **ringing noises** in the ears (tinnitus), and/or **vertigo**, **nausea** and **vomiting** are the usual presenting features. This condition must be distinguished from the other major cause of these symptoms in divers – inner ear barotrauma (see Chapter 9).

LUNGS or PULMONARY DCS

Nitrogen bubbles are frequently found in the veins of divers ascending after deep dives, without necessarily the development of overt clinical DCS. When large numbers of these bubbles form, they may become trapped in the small vessels of the lungs, obstructing the blood flow. If excessive bubbles occur, this leads to a disturbance of lung function and a feeling of **breathlessness**, known as the "**chokes**".

Clinical features also include a **tight feeling in the chest**, **chest pain**, **difficult** and **rapid breathing**. Coughing is often observed, and may be precipitated by smoking, hyperventilating or exercise. Frequently the symptoms come on very soon after ascent, from relatively deep dives (over 30 metres) or after prolonged dives. Death may supervene.

HEART or CARDIAC DCS

The nitrogen bubbles that commonly form in the veins of divers after deep dives are usually filtered by the lung vessels.

There is a condition affecting the heart (**patent foramen ovale – PFO**) which is sometimes claimed to be present in about 30% of the population, and in which there is a potential communication between the right and left sides of the heart – between the right and left atria. It is a flap valve, normally kept closed by the naturally higher pressure on the left side (left atrium) of the heart. When large amounts of nitrogen bubbles obstruct the lungs, the back pressure in the right atrium can exceed the pressure in the left atrium. This flap may then open allowing gas bubbles to pass from the right to the left side of the heart, and then be pumped and distributed to any part of the body (similar to arterial gas embolism resulting from a burst lung – see Chapter 11).

Bubbles passing through a patent foramen ovale (PFO), or any other cardiac defects, tend to rise because of buoyancy. They can be easily carried into the blood vessels supplying the brain because it has a large blood supply and is located above the heart. This is one cause of cerebral DCS after apparently so called "safe" dives. It may be called cerebral arterial gas embolism or **CAGE**, but is due to DCS, and not pulmonary barotrauma. The term **acute decompression illness** covers both causes.

Bubbles can occasionally pass down the coronary arteries, which supply the heart, restricting the blood supply to the heart itself. In severe instances this can lead to a fatal destruction of heart muscle (myocardial infarction) just as for a "heart attack" in a non-diving person. In other cases, life threatening disturbances in cardiac pumping and rhythm may result.

Cardiac symptoms include chest pain, palpitations and shortness of breath.

GASTROINTESTINAL DCS

Obstruction of blood flow to the intestines by nitrogen bubbles can occasionally affect the gut. Clinical features are not common, but can include **vomiting** or **diarrhoea**, **cramping abdominal pain** and **haemorrhage** into the gut. Severe cases can show clinical shock, and can bleed to death.

SKIN MANIFESTATIONS of DCS

These are not common in scuba divers who wear wet suits.

Itching of the arms and legs, sometimes with a rash, is not uncommon after deep recompression chamber dives and with dry suits. This condition is probably due to gas passing from the surrounding high pressure atmosphere into the skin. The condition is not serious and requires no treatment.

In more severe DCS, nitrogen bubbles in the blood can obstruct blood supply to the skin, causing patchy white, blue and pink areas – "**marbling**". Obstruction of the lymphatic system (drainage of tissues) may produce **localised swelling of skin**.

GENERAL SYMPTOMS of DCS

Apathy, tiredness, malaise, and a **generalised weakened state** are common observations in many cases of DCS. In very severe cases there may be **generalised internal haemorrhages, shock,** and/or **death**.

DELAYED SYMPTOMS of DCS

Prolonged symptoms may be due to damaged nerve, spinal cord or brain (see above), body tissues or bone (see Chapter 17). In these cases there can be a persistence or recurrence of symptoms. Various psychological problems can also supervene on DCS. Even the stressful treatments and peer recriminations can exact an emotional toll on divers. Anxiety states and post-traumatic stress disorders are not uncommon sequelae

EVOLUTION OF SYMPTOMS

In general, the slower symptoms are to develop after ascent, the less serious the DCS, and *vice versa*. Also, the longer the delay between ascent and symptoms (say, 6-24 hours), the fewer and slower subsequent symptoms are to develop. The corollary of this is:

With symptoms developing soon after the ascent, the DCS is likely to be more serious.

In assessing DCS, the time of onset of symptoms should be related to the time of ascent. The clinical manifestations and their evolution should be described, together with any aggravating factors.

The manifestations may be progressive (getting worse), static or improving. They may also relapse.

Aggravating factors include not only those that predispose to DCS, but also those that precipitate it (see Chapter 13).

A major observation, supporting the diagnosis of DCS, is the favourable response of DCS to raised environmental pressure (re-immersion in the water, treatment in a recompression chamber) and, with a slower response, administration of 100% O₂.

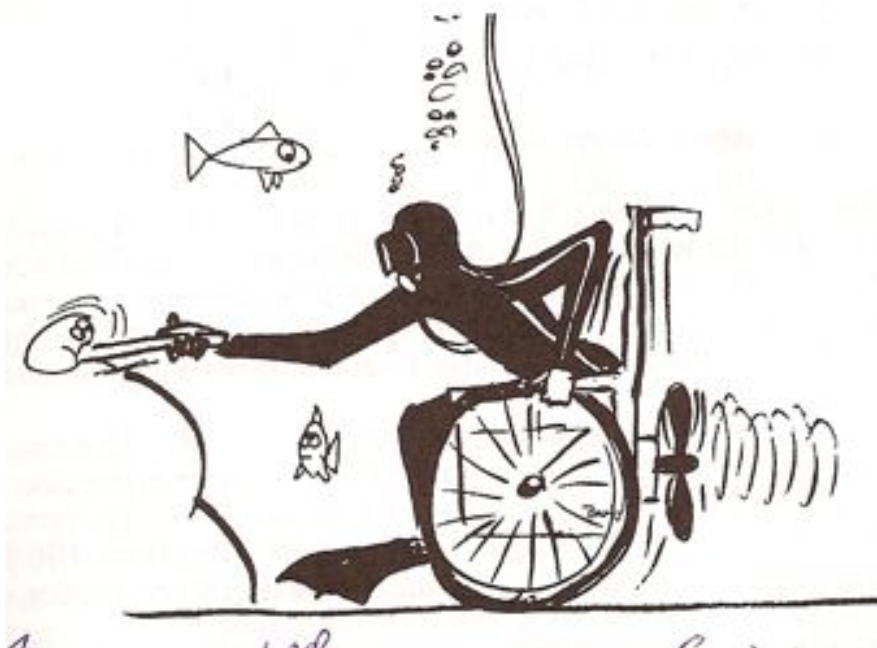


Fig. 15.1

The **ABBREVIATED MENTAL TEST SCORE (AMTS)** can be used to assess mild delirium, confusion and other cognitive impairment.

The following questions are put to the patient. Each question correctly answered scores one point. A score of 6 or less indicates impairment of brain function. A score above 6 does NOT mean that there is no cognitive impairment

Question

What is your age? (1 point)

What is the time to the nearest hour? (1 point)

Give the patient an address, and ask him or her to repeat it at the end of the test. (1 point)
e.g. 36 Smithsonian Street

What is the year? (1 point)

What is the name of the hospital or number of the residence where the patient is situated? (1 point)

Can the patient recognise two persons (the doctor, nurse, home help, etc.)? (1 point)

What is your date of birth? (day and month sufficient) (1 point)

In what year did World War 1 begin? (1 point)

(other well known dates can be used, with a preference for dates some time in the past.)

Name the present monarch/prime minister/president. (1 point)

(Alternatively, the question "When did you come to [this country]?" has been suggested)

Count backwards from 20 down to 1. (1 point)

As well as a "spot check", this test can be used to indicate improvement or deterioration, if repeated. It is not as comprehensive as others, which may be employed by paramedics and doctors e.g. the Mini-Mental State Examination, or the TYM.